Effect of *Notchi kudineer* (*Vitex negundo* aqueous extract) on surgically induced Endometriosis in Sprague Dawley rats

Arul Amuthan,[1] Shabari Anandh,[2] Syed Musharraf,[3] Nupur Agarwal,[4] Vasudha Devi,[1] Revathi P Shenoy,[4] Bhavna Nayal[5]

[1]*Department of Pharmacology, Melaka Manipal Medical College, Manipal University, Karnataka-576104, INDIA.*

[2]*Department of Pharmacology, MVJ Medical College and Research hospital, Hoskote, Bangalore-562 114, INDIA.*

[3]*Department of Pharmacology, Kasturba Medical college, Manipal University, Manipal-576104, INDIA.*

[4]*Department of Biochemistry, Kasturba Medical College, Manipal University, Manipal-576104, INDIA.*

[5]*Department of Pathology, Kasturba Medical College, Manipal University, Manipal-576104, INDIA.*

ABSTRACT

Background: Endometriosis is the growth of endometrial tissue in ectopic places outside the uterus. Siddha physicians claim that *Vitex negundo* leaf decoction reduces the symptoms of endometriosis in clinical practice. **Objective:** To evaluate the effect of *Vitex negundo* aqueous extract on surgically induced endometriosis in Sprague Dawley rats. **Materials and Methods:** Endometriosis was surgically induced in nulliparous female Sprague Dawley rats with regular estrus cycle by autografting endometrium tissue on posterior abdominal wall. After 30 days of implantation, rats were allocated into two groups (n = 6). Control group did not receive any drug, whereas test group received an oral dose of *Vitex negundo* aqueous extract (300 mg/kg) for 30 days. After 30 days of treatment, the endometriosis cyst size and adhesion were measured and blood was collected for hematology. Malondialdehyde (MDA, an oxidant) and thiol (antioxidant) levels were estimated in blood as well as in cyst. Endometriosis cyst was studied for histopathological grading. Statistical analysis was done using independent t test by keeping $p < 0.05$. **Results:** Test drug reduced the adhesion and cyst size compared to control, but the difference was not statistically significant. Histological grade was reduced from 3 to 0 in test group. The test drug significantly increased thiol in blood ($p = 0.016$), and also reduced the blood MDA level ($p = 0.001$) compared to control. Test drug increased the red blood cell distribution width (RDW_CV: $p = 0.009$ and RDW_SD: $p = 0.003$), platelet ($p = 0.03$) and plateletcrit ($p = 0.026$) compared to control group. **Conclusion:** Our study has created the scientific evidence for the siddha physician's claim on *Vitex negundo* by demonstrating reduction in endometriosis cyst size, adhesion, histological grading and oxidant levels as well as elevation in antioxidant level.

Key words: Vitex negundo, Endometriosis , Sprague Dawley Rats, Antioxidants.

Citation: Amuthan A, Anandh S, Musharraf S, Agarwal N, Devi V, Shenoy RP, Nayal B. Effect of *Notchi kudineer* (*Vitex negundo* aqueous extract) on surgically induced endometriosis in Sprague Dawley rats . Int J Pharmacol and Clin Sci. 2015;4(3):35-43.

INTRODUCTION

Endometriosis is a progressive disease characterized by growth of endometrial stromal and glandular tissues in ectopic places outside the uterus which leads to firm adhesion formation. Adhesion in pelvic area can destroy normal anatomy of female genital tract. Endometriosis affects 10% of women in reproductive age. It is a major cause of infertility and gynecological problems such as dysmenorrhea, chronic pelvic pain and dyspareunia in young reproductive women.[1] Augmented endometrial

Received : 22-04-2015 **Revised :** 12-08-2015; **Accepted :** 17-08-2015

***Correspondence : Dr. Vasudha Devi, Department of Pharmacology, Melaka Manipal Medical College, Manipal University, Karnataka – 576104, INDIA.**
Email: v21devi@gmail.com

Conflict of interest: Nil ; **Source of support :** ICMR

Copyright: © 2015 Journal. All rights reserved.

DOI : 10.5530/ijpcs.4.3.1

cell survival leads to vigorous proliferation and invasion in the peritoneum. Neovascularization in endometriosis is associated with development of pain carrying nerve fibers cause chronic pelvic pain.[2] Studies have shown increased number of activated mast cells in the endometriosis lesion. By releasing inflammatory mediators, cytokines and certain growth factors (colony stimulating factor, TNF-alfa, Stem cell factor etc.), mast cells have a strong role in the development of endometriosis lesion.[3] Matrix metalloproteinase (MMPs) are involved in the adherence of endometrial tissue in the peritoneal lining and suppression of MMPs inhibited the establishment of ectopic lesions by human endometrium in nude mice.[4] Endometriotic tissue comprises non-transformed cells only. However, it shares several features with neoplasms (uncontrolled growth, invasion of adjacent tissues, defective apoptosis, sustained local inflammatory responses). Conversely, endometriosis increases the risk of ovarian cancer, in particular invasive low-grade serous, clear-cell, and endometrioid subtypes of the neoplasm.[5] Many recent studies have focused on the role of macrophages in the neovascularization, survival and the growth of lesion.[6] Till now, there is there is no promising drug with less adverse effect has been discovered for endometriosis. Thus, there is a search for drug from traditional medicines.

Siddha medicine is one of the Traditional medical system of Asian subcontinent. The *soothaga nool*-300 (a siddha text for gynaecology) describes the endometriosis as '*salasoolai*' (pain due to retention of menstrual fluid in abdomen). *Arivaiyar chinthaamani* (a siddha text describes the disease of women during reproductive age) describes as *karukkuzhi vaatham* (abnormal function of uterine endometrium). During our survey among Siddha practitioners, we found that they prescribe *Vitex negundo* aqueous extract to reduce the symptoms of endometriosis. This plant has been studied and proved for anti-inflammatory, central nervous system depressant, antifungal, antibacterial, antioxidant, anticonvulsant, antiallergic, cytotoxic, hepatoprotective, laxative, hypoglycaemic and immunomodulatory activities. The plant also has snake venom neutralizing property.[7] The objective of the study was to evaluate the effect of *Vitex negundo* aqueous extract on surgically induced endometriosis in Sprague Dawley rats.

MATERIALS AND METHODS

Plant extract

Vitex negundo leaves were collected locally around Manipal area, India, which was authenticated by a Taxonomist of SDM Centre for Research in Ayurveda and Allied Sciences, Udupi, India.

The *notchi kudineer* (aqueous extract) was taken by boiling 100 gm of dried leaves with 400 ml of water for 60 minutes in slow flame. Then, it was filtered and dried up in the water bath. Subsequently, the extract was stored in the desiccator. For the study purpose, the extract was mixed with distilled water for the administration to rats. In addition, preliminary phytochemical screening was done.

HPTLC fingerprint of *notchi kudineer*

The 1 gm aqueous extract of *Vitex negundo* was fractionated with 10 ml of methanol and 4, 8 and 12 µl of the methanol soluble portion were applied on a pre-coated silica gel F_{254} on aluminum plates to a band width of 7 mm using Linomat 5 TLC applicator. The HPTLC plate for the extract was developed in ethyl acetate: glacial acetic acid: water (8.0: 1.0: 1.0). The developed plates were visualized in UV 254, 366, 540 (White light) and scanned under UV 254 nm, 366 nm, 540 nm and 620 nm post derivatization. R_f, colour of the spots and densitometric scan were recorded.

ANIMALS

The study was undertaken after getting approval from Institutional Animal Ethics Committee (Ref. No: IAEC/KMC/45/2013). Adult nulligravid Sprague Dawley female rats weighing 200–250 g, bred locally in the animal house of Kasturba Medical College, Manipal were used. Animals were housed in polypropylene cages, fed with a standard pellet and water *ad libitum*.

Surgical procedures and experimental design

First operation: induction of endometriosis:[8,9]

Endometriosis lesion was surgically induced as described in established models. In brief, under general anesthesia (ketamine 60 mg/kg and xylazine7 mg/kg), left uterine horn was removed using scissors and kept in the petri dish containing physiological phosphate buffer solution. The uterine horn was cut opened longitudinally using the scissors. By using a 2 mm punch biopsy needle, 2 pieces of endometrium of uterus with myometrium were removed, which were subsequently implanted by suturing to the posterior peritoneal wall near the arterial bifurcation using a suture thread (Figure1A-1E). Then, the abdomen was closed by suture. The rats were injected with gentamycin (0.1 ml) for 3 consecutive days after finishing the surgery. Rats were allowed to develop endometriosis for about 30 days.

Second operation: evaluation of the endometriosis foci and randomization of the rats

One month after the implantation, the second operation was performed. Under general anesthesia, abdominal incision was done and the implants were observed for the development of endometriosis cysts (Figure 2). The cysts were measured by three dimensions (length × width × height in millimeters) using a ruler. The spherical volume of each ectopic endometriosis cyst was calculated using the prolate ellipsoid formula: $V(mm^3)=(0.52\times length\times width\times height)$.[10] The adhesions were scored according to Blauer's scoring system[11] as follows: 0–no adhesion; 1–thin, easily separable adhesions, 2–thick adhesions limited to one area; 3–thick and widespread adhesions; 4–thick and widespread adhesions plus adhesions of viscera to the anterior/posterior abdominal wall (Figure 3).

Again, the abdomen was closed by suturing. The animal which had not developed cyst was excluded from the further study. The rats with endometriosis cyst were randomized into two groups (n=6); group 1 (Control) did not receive any treatment and group 2 (Test) received *Vitex negundo* aqueous extract (300 mg/kg) for next 30 days. This dose was derived from acute toxicity study done in our lab.

Figure 1A: The procedure to remove the left uterine horn

Third operation: effects of Vitex negundo on hematology and endometriosis cyst

After 30 days treatment with *Vitex negundo* aqueous extract, blood was collected by retro orbital method for haematology parameters and to estimate malondialdehyde (MDA, an oxidant) and thiol (antioxidant) level in blood. The rats were operated under general anesthesia to assess adhesion score and cyst volume.

Cyst collection for oxidant levels and histopathological analysis

One cyst from each animal was preserved in phosphate buffer solution for the estimation of malondialdehyde (MDA, an oxidant) and thiol (antioxidant) level. Another cyst was fixed in 10% formaldehyde solution. The tissues were embedded in paraffin after routine dehydration, and 5 mm thick sections were made with a microtome. The samples were stained with hematoxylin and eosin (H & E), and examined under alight microscope. The pathologist who assessed the samples was blinded to the treatment groups. The histological grading for endometriosis was done based on morphology of endometrial glands and stromas[12] as follows: Grade 3–well preserved epithelial layers; Grade 2–moderately preserved epithelium with leucocyte infiltration; Grade 1–poorly preserved epithelium (occasional epithelial cells only); Grade 0-no epithelium. The tissues were also stained with Toluidine blue to view both the granulated and degranulated mast cells.

Figure 1B: The removed uterine horn was kept in a petri dish containing physiological phosphate buffer solution

Figure 1C: The uterine horn was cut opened longitudinally using the scissors

Figure 1D: The 2-mm sized endometrium with myometrium was ready to suture

Figure 1E: The endometrium of uterus with myometrium was implanted by suturing to the posterior abdominal wall near the arterial bifurcation

Figure 2: Endometrial cysts filled with fluid

Figure 3: Thick adhesion of viscera (fundus of the stomach) to the posterior abdominal wall (grade 4)



Figure 4A: HPTLC photo documentation of ethanol extract of Vitex negundo

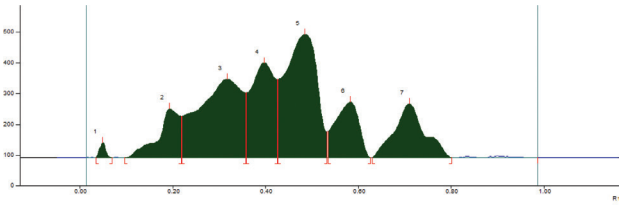

Peak	Start Position	Start Height	Max Position	Max Height	Max %	End Position	End Height	Area	Area %
1	0.04 Rf	0.1 AU	0.05 Rf	49.4 AU	3.23 %	0.07 Rf	0.1 AU	458.1 AU	0.67 %
2	0.10 Rf	0.0 AU	0.19 Rf	158.8 AU	10.39 %	0.22 Rf	34.8 AU	5334.5 AU	7.77 %
3	0.22 Rf	134.9 AU	0.32 Rf	255.1 AU	16.69 %	0.36 Rf	11.0 AU	17090.2 AU	24.89 %
4	0.36 Rf	211.2 AU	0.40 Rf	308.4 AU	20.17 %	0.43 Rf	54.0 AU	11223.0 AU	16.35 %
5	0.43 Rf	254.0 AU	0.49 Rf	401.1 AU	26.24 %	0.53 Rf	84.4 AU	19799.0 AU	28.84 %
6	0.54 Rf	85.4 AU	0.58 Rf	180.8 AU	11.83 %	0.63 Rf	0.1 AU	6630.3 AU	9.66 %
7	0.63 Rf	0.3 AU	0.71 Rf	174.8 AU	11.44 %	0.80 Rf	0.1 AU	8117.9 AU	11.82 %

Figure 4B: Densitometric scan of aqueous extract of Vitex negundo at 254 nm

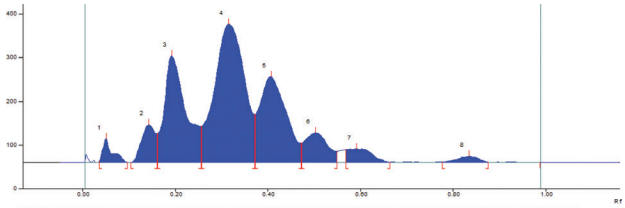

Peak	Start Position	Start Height	Max Position	Max Height	Max %	End Position	End Height	Area	Area %
1	0.04 Rf	2.6 AU	0.05 Rf	54.5 AU	5.39 %	0.10 Rf	0.3 AU	821.6 AU	2.18 %
2	0.10 Rf	0.1 AU	0.14 Rf	86.7 AU	8.58 %	0.16 Rf	66.0 AU	1854.6 AU	4.92 %
3	0.16 Rf	66.5 AU	0.19 Rf	243.2 AU	24.05 %	0.26 Rf	83.0 AU	8173.2 AU	21.67 %
4	0.26 Rf	83.3 AU	0.32 Rf	316.2 AU	31.26 %	0.37 Rf	09.8 AU	14713.4 AU	39.01 %
5	0.37 Rf	110.8 AU	0.41 Rf	196.6 AU	19.44 %	0.47 Rf	44.3 AU	8039.3 AU	21.32 %
6	0.47 Rf	44.7 AU	0.50 Rf	67.7 AU	6.69 %	0.55 Rf	25.6 AU	2408.9 AU	6.39 %
7	0.57 Rf	29.3 AU	0.59 Rf	31.7 AU	3.14 %	0.66 Rf	0.5 AU	1219.7 AU	3.23 %
8	0.78 Rf	1.1 AU	0.84 Rf	14.7 AU	1.45 %	0.88 Rf	0.6 AU	481.7 AU	1.28 %

Figure 4C: Densitometric scan of aqueous extract of Vitex negundo at 366 nm

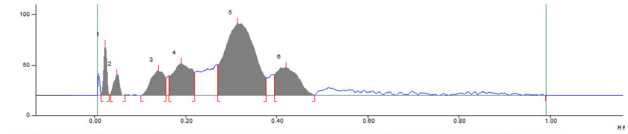

Peak	Start Position	Start Height	Max Position	Max Height	Max %	End Position	End Height	Area	Area %
1	0.01 Rf	1.1 AU	0.02 Rf	49.4 AU	22.01 %	0.03 Rf	0.3 AU	244.8 AU	3.95 %
2	0.04 Rf	0.8 AU	0.05 Rf	20.7 AU	9.20 %	0.07 Rf	0.5 AU	184.0 AU	2.97 %
3	0.10 Rf	0.0 AU	0.14 Rf	24.6 AU	10.93 %	0.16 Rf	17.7 AU	535.1 AU	8.64 %
4	0.16 Rf	19.2 AU	0.19 Rf	31.3 AU	13.92 %	0.22 Rf	22.9 AU	944.5 AU	15.25 %
5	0.27 Rf	30.1 AU	0.31 Rf	71.2 AU	31.71 %	0.38 Rf	18.1 AU	3321.1 AU	53.63 %
6	0.40 Rf	20.2 AU	0.42 Rf	27.5 AU	12.22 %	0.48 Rf	0.6 AU	963.2 AU	15.55 %

Figure 4D: Densitometric scan of aqueous extract of Vitex negundo at 540 nm

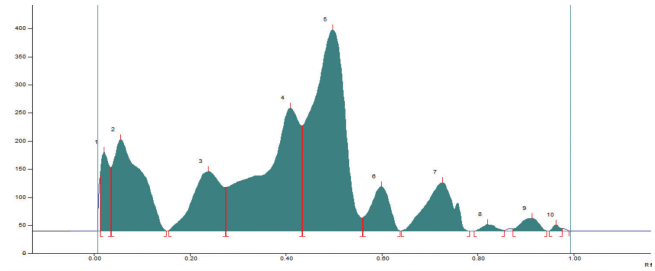

Peak	Start Position	Start Height	Max Position	Max Height	Max %	End Position	End Height	Area	Area %
1	0.01 Rf	98.8 AU	0.02 Rf	140.5 AU	11.74 %	0.04 Rf	12.6 AU	1870.8 AU	3.77 %
2	0.04 Rf	113.9 AU	0.06 Rf	162.6 AU	13.59 %	0.15 Rf	0.2 AU	6814.2 AU	13.72 %
3	0.16 Rf	0.6 AU	0.24 Rf	105.7 AU	8.83 %	0.27 Rf	77.7 AU	4574.5 AU	9.21 %
4	0.28 Rf	77.8 AU	0.41 Rf	219.1 AU	18.31 %	0.43 Rf	87.2 AU	12666.7 AU	25.50 %
5	0.44 Rf	187.8 AU	0.50 Rf	357.9 AU	29.92 %	0.56 Rf	23.8 AU	17018.3 AU	34.26 %
6	0.56 Rf	24.2 AU	0.60 Rf	79.1 AU	6.61 %	0.64 Rf	0.1 AU	2203.4 AU	4.44 %
7	0.64 Rf	0.2 AU	0.73 Rf	86.2 AU	7.20 %	0.78 Rf	0.1 AU	3585.5 AU	7.22 %
8	0.79 Rf	0.3 AU	0.82 Rf	11.8 AU	0.98 %	0.86 Rf	1.2 AU	239.0 AU	0.48 %
9	0.87 Rf	3.6 AU	0.91 Rf	22.6 AU	1.89 %	0.95 Rf	0.1 AU	594.3 AU	1.20 %
10	0.95 Rf	0.2 AU	0.96 Rf	11.1 AU	0.93 %	0.98 Rf	4.4 AU	113.6 AU	0.23 %

Figure 4E: Densitometric scan of aqueous extract of Vitex negundo at 620 nm

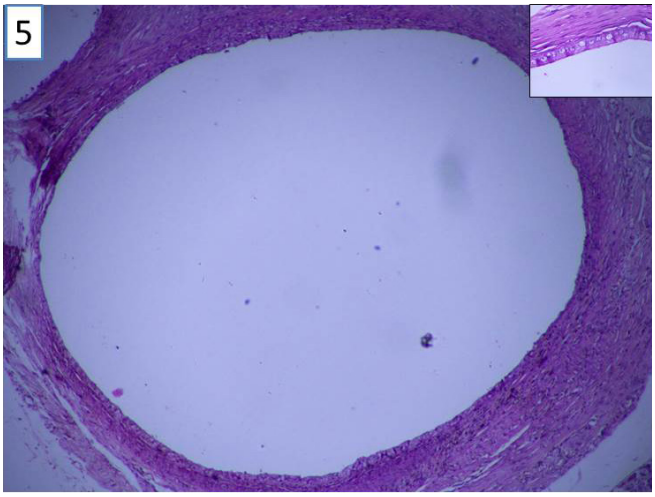

Figure 5: H & E staining of endometrial cyst in control group showed the cavity lined with well-presented epithelial layer (grade 3)

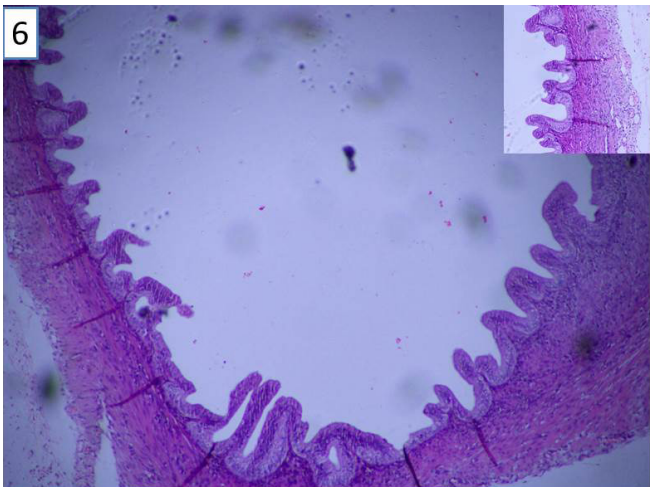

Figure 6: H & E staining of endometrial cyst in control group showed the cavity lined with well-presented epithelial layer (grade 3)

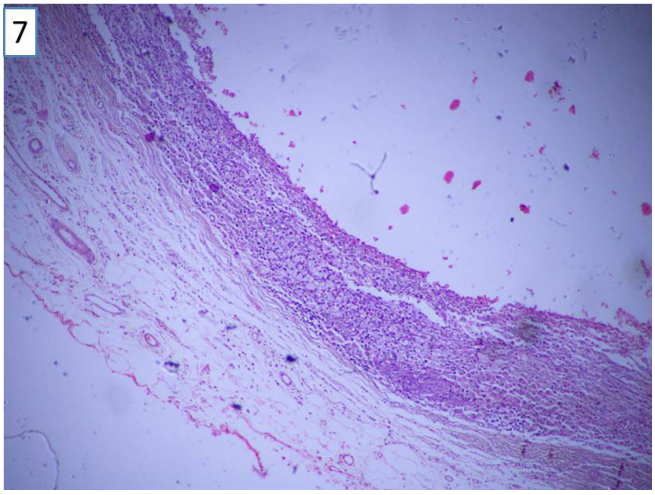

Figure 7: H & E staining of Vitex negundo treated endometrial cyst showed no epithelial lining (grade 0)

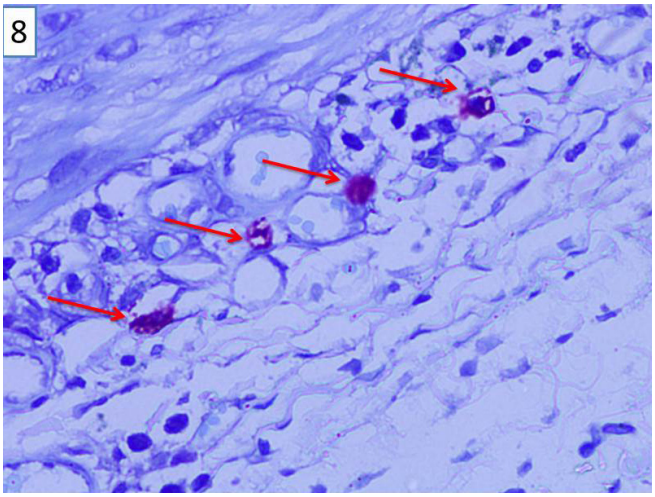

Figure 8: Toluidine blue staining of endometrial cyst showed deep violet/red purple colored (indicated by red arrow) mast cells in a blue background. Granulated mast cells are filled with granules.

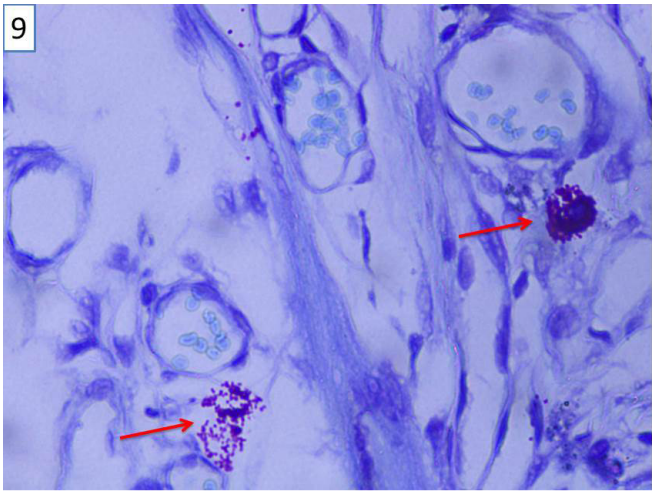

Figure 9: Toluidine blue staining of endometrial cyst showed deep violet/red purple colored (indicated by red arrow) mast cells in a blue background. The degranulation includes > 3 granules outside the mast cells

Table 1: R_f values of of aqueous extract of *Vitex negundo*

254 nm	366 nm	540 nm	Post derivatisation
-	0.10 (FL. blue)	-	0.10 (D. purple)
-	0.15 (FD. blue)	-	-
0.17 (D. green)	-	-	-
-	0.20 (FL. blue)	-	0.20 (D. purple)
-	0.26 (FD. blue)	-	-
0.28 (D. green)	-	0.28 (L. yellow)	0.28 (D. orange)
0.35 (D. green)	0.35 (FL. blue)	-	0.35 (D. purple)
-	0.37 (FL. blue)	-	-
0.42 (D. green)	0.42 (FL. blue)	-	-
-	-	-	0.44 (D. purple)
0.52 (D. green)	0.52 (FL. blue)	-	0.52 (D. pink)
0.64 (D. green)	-	-	0.64 (D. pink)
0.67 (L. green)	-	-	-
-	-	0.70 (L. yellow)	-
-	-	-	0.73 (L. pink)
-	-	-	0.81 (L. orange)

*L-Light; D-Dark; F-Fluorescent.

Table 2: Effect of 30 days treatment with *Vitex negundo* on body weight and organ weights in rats with endometriosis

Groups	Body weight in gm			Organ weight (mg)	
	Pretreatment	After 30 days drug therapy	Difference in body weight	Uterus	Ovary
Control	204.86 ± 18.46	237.86 ± 16.52	33 ± 26.50	535 ± 61	305 ± 39
***Vitex negundo* (300 mg/kg)**	224.17 ± 12.96	232.33 ± 20.83	8.17 ± 5.30*	660 ± 98	214 ± 32

Values are expressed in mean ± SD, *p=0.046 (independent T test).

Table 3: Effect of 30 days treatment with *Vitex negundo* on adhesion score and endometriosis cyst size/volume

Group	Adhesion score		cyst size	
	Control	*Vitex negundo*	Control	*Vitex negundo* (300 mg/kg)
Pretreatment	2 (1, 3)	1.5 (1, 2.25)	1.75 (0.52, 15.60)	62.4 (8.35, 468.00)
After 30 days drug	2 (1, 3)	0.5 (0, 1.75)	31.2 (0.52, 104.00)	42.08 (5.05, 95.16)
Difference in adhesion	0	-1.0 (-1.0, -0.5)	+28.08 (0, +83.2)	-39.95 (-374.4,+8.25)

Values are expressed in median and interquartile range.

Statistical analysis

Depending on the distribution of the data, mean and standard deviation or median and interquartile range were used to summarize the data. The data were analyzed using SPSS software (11.0 version) by keeping $p<0.05$ as statistically significant.

RESULT

Vitex negundo aqueous extract standardization

The phytochemical screening of *Vitex negundo* aqueous extract showed presence of carbohydrate, coumarins, flavonoids, phenol, resins, saponins, tannin and terpenoid. HPTLC fingerprint with R_f values, photo documentation,

Table 4: Effect of 30 days treatment with *Vitex negundo* on hematology parameters

Parameters	Control	*Vitex negundo* (300 mg/kg)
White Blood Cells (103/µL)	5.33 ± 0.76	6.28 ± 1.61
Red Blood Cells (106/µL)	6.8 ± 0.22	7.02 ± 1.18
Hemoglobin (g/dL)	13.83 ± 1.43	14.33 ± 2.19
Hematocrit (%)	40.33 ± 3.20	42.96 ± 4.80
Mean corpuscular volume (fL)	59.46 ± 1.16	61.90 ± 6.14
Mean corpuscular hemoglobin (pg)	20.26 ± 0.54	20.46 ± 1.26
MCHC (g/dL)	34.20 ± 0.90	33.26 ± 2.56
RDW_CV (%)	14.70 ± 0.54	18.51 ± 4.35*
RDW_SD (fL)	31.73 ± 0.87	40.70 ± 11.33†
Platelet (103/µL)	662.67 ± 35.79	723.17 ± 229.52 ‡
Mean platelet volume (fL)	6.2 ± 0.62	7.58 ± 0.81
platelet distribution width	15.63 ± 0.67	17.01 ± 0.59
Plateletcrit (PCT (%)	0.40 ± 0.02	0.53 ± 0.13 §

MCHC-*mean corpuscular hemoglobin concentration*.
RDW_CV- Red blood cell distribution width-coefficient of variationRDW_SD-Red blood cell distribution width-standard deviation
Values are expressed in mean ± SD.* p=0.009, † p=0.003, ‡p=0.03, §p=0.026 vs. control (independent samples T test).

Table 5: Effect of 30 days treatment with *Vitex negundo* on oxidant and antioxidant level in blood and endometriosis cyst

Group	Blood (mean ± SD)		Endometriosis cyst§	
	Thiol	MDA	Thiol	MDA
Control	363.33 ± 25.81	4.06 ± 1.13	2.05 (2.05, 11.6)	2.20 (2.20, 11.0)
Vitex negundo(300mg/kg)	503.33 ± 115.35*	1.53 ± 0.72	11.9 (6.75, 13.5)	9.5 (6.5, 14.0)

§Values are expressed in median and interquartile range.
MDA–Malondialdehyde, * p=0.004 vs. control.

densitometric scan at different wavelengths (254 nm, 366 nm, 540 nm) were recorded and presented as follows; (Figure 4A-4E, Table 1). Around 16 peaks (R_f values) were identified in different wavelengths.

Body weight of animal

Control group rats gained 33 gm of body weight in 30 days after inducing endometriosis. Whereas, the test group treated with *Vitex negundo* for 30 days gained only 8 gm of body weight. The body weight gain was significantly lesser (p=0.046) in extract treated group compared to control (Table 2).

Endometrial cyst volume and adhesion scoring

Vitex negundo extract reduced the adhesion and cyst size compared to control. However, it was statistically not significant compared to control (Table3).

Haematology

There are no major changes due to *Vitex negundo* treatment except significant increase in red blood cell distribution width (RDW_CV: p=0.009 and RDW_SD: p=0.003), platelet (p=0.03) and plateletcrit (p=0.026) compared to control group (Table 4).

Biochemical parameters:

Vitex negundo treatment significantly increased the antioxidant (thiol) level in blood (p=0.004). It also increased the thiol level in endometriosis cyst, but it was not statistically significant (Table 5).

Histology

Histology of all endometriosis cysts in control group showed cavity lined with well-presented epithelial layer (grade 3)

with the high eosinophils, lymphocytes, macrophages and mast cells in stroma (Figure 5, 6). Whereas, *Vitex negundo* treated endometrial cyst had Grade 0 histopathological changes as no epithelial lining was observed (Figure 7). It was observed that control group has more number of mast cells and majority was in degranulated state compared to test group (Figure 8, 9).

DISCUSSION

The ectopic endometrial cells are similar to the normal endometrium present within uterus, answering to the same hormonal stimulus although they have different level of enzymatic activities. It is still known that the estrogen stimulates the growth of the ectopic endometrial tissue because endometriosis is not found before the first menstruation, as well as after the menopause.[13] The pathophysiology of endometriosis involves a complex interaction between ectopic endometrial tissue and host peritoneal tissues. The role of estrogen, mast cells, macrophages, and angiogenesis factors in adhesion and metastasis have been studied in detail. The molecular mechanisms of disease progression involves in inflammation, healing and repair, cell proliferation, modulation of hormonal receptors and activation of anti-apoptosis. The current drug discovery is focused on the above targets.

In this study, *Vitex negundo* aqueous extract was studied for its beneficial effect against induced endometriosis in rats. Characteristic features of endometrial cysts and adhesions were similar to that are seen clinically. Our study showed that *Vitex negundo* reduced the endometrial cyst size and destroyed the endometrial epithelial morphology. Ethanolic extracts of seeds of *Vitex negundo* Linn. had shown estrogen-like activity which propounded its use in hormone replacement therapy.[14] In our study, aqueous extract of leaves decreased endometrial cyst size. It might be due the presence of high polar phytochemicals having anti-endometriotic property that were present only in the aqueous extract. The plant has been already proven for its anti-inflammatory and antioxidant activity.[15] The drug which can show effect on ectopic endometriosis tissue also shows the same effect in the intra uterine endometrium.

In our study, the uterine weight was not significantly affected due to the extract compare to control. This is another important observation that the extract did not act on intrauterine endometrium, but acted on endometriosis to reduce its size, thus there is a possible to hypotheses that the extract might have specific action in ectopic endometriosis tissues. The possible molecular mechanisms of the extract might be specific to endometriosis pathogenesis either modulating estrogen receptor or modulating other pathways that occur only in ectopic endometrial tissues.

The adhesion lysis can be achieved by inhibiting activity of matrix metalloproteinase and collagen. Since the adhesion is the common complication of surgery and laparoscopy, the extract could be studied in these models too. Our study also showed the reduction in mast cells and macrophages revealing the possible anti-endometriotic mechanism aqueous extract of *Vitex negundo* mediated through mast cells and macrophages. Our observation is supported by the earlier study which demonstrated its mast cell stabilizing activity.[16] It may be possible to have multiple synergistic mechanisms due the presence of multiple phytochemicals such as carbohydrate, coumarins, flavonoids, phenol, resins, saponins, tannin and terpenoid.

We conclude that the traditional Siddha Medicine claim of *Vitex negundo* in the treatment of endometriosis has some scientific basis. Further, studies are mandatory to isolate the phytochemical(s) to evaluate the mechanism and the synergistic activity with existing drugs and also clinical trials to optimize the treatment protocol.

REFERENCES

1. Grummer R. Animal models in endometriosis research. Human Reproductive Update. 2006;12(5):641-9.
2. Berkley KJ, Dmitrieva N, Curtis KS, Papka RE. Innervation of ectopic endometrium in a rat model of endometriosis. Proc Natl AcadSci USA. 2004;101(30):11094-8.
3. Kempuraj D, Papadopoulou N, Stanford EJ, Christodoulou S, Madhappan B, Sant GR. Increase number of activated mast cells in endometriosis lesions positive for corticotropin-releasing hormone and urocortin. American Journal of Reproductive Immunology. 2004;52:267-75.
4. Bruner KL, Matrisian LM, Rodgers WH, Gorstein F, Osteen KG. Suppression of matrix metalloproteinase inhibits establishment of ectopic lesions by human endometrium in nude mice. J Clin Invest. 1997;99(12):2851-7.
5. Pearce CL, Templeman C, Rossing MA, Lee A, Near AM, Webb PM. Association between endometriosis and risk of histological subtypes of ovarian can- cer: a pooled analysis of case-control studies. Lancet Onco. l2012;13(4):385-94.
6. Capobiano A, Rovere-Querini P. Endometriosis, a disease of the macrophage. Frontimmun 2013;4: 9. doi: 10.3389/fimmu.2013.00009.
7. Ladda PL, Magdum CS. Vitex negundo Linn.: Ethnobotany, Phytochemistry and Pharmacology-A Review. International Journal of Advances in Pharmacy, Biology and Chemistry. 2012;1(1): 111-20.
8. Becker CM, Wright RD, Satchi-Fainaro R, Funakoshi T, Folkman J, Kung AL. A novel noninvasive model of endometriosis for

monitoring the efficacy of antiangiogenic therapy. Am JPathol. 2006;168(6):2074-84.
9. Shi J, Ge BZ, Yin Y, Li Yd, Shou J. Acupuncture improves the effects of Chinese herbal medicine in treating endometriosis model rats. The Journal of Animal and Plant Sciences. 2013;23(1): 293-303.
10. Yildirim G, Attar R, Ozkan F, Kumbak B, Ficicioglu C, Yesildaglar N. The effects of letrozole and melatonin on surgically induced endometriosis in a rat model: a preliminary study. Fertil Steril. 2010;93(6):1787-92.
11. Mohammadzadeh A, Heidari M, Ghoraii HS, Zarnani AH, Novin MG, Akhondi MM. Induciton of Endometiosis by implantation of endometrial fragments in female rats. Iranian Journal of Reproductive Medicine. 2006:4(2):63-7.
12. Yildirim G, Attar R, Ficicioglu C, Karateke A, Ozkan F, Yesildaglar N. Etanercept causes regreesion of endometiotic implants in a rat model. Arch Gynecol Obstet. 2011;283(6):1297-302.
13. Vyas S, Gangar K. Postmenopausal oestrogens and Arteries. Br J Obstetric Gyneco. l1995;102(12):942-6.
14. Das S, Parveen S, Kundra CP, Pereira BM. Reproduction in male rats is vulnerable to treatment with the flavonoid-rich seed extracts of *Vitex negundo*. Phytother Res. 2004;18(1):8-13.
15. Tandon VR, Gupta RK. Anti-inflammatory Activity and Mechanism of Action of *Vitex negundo* Linn. International Journal of Pharmacology. 2006;2(3):303-8.
16. Patel J, Shah S, Deshpande S, Shah G. Evaluation of the antiasthmatic activity of leaves of *Vitex negundo*. Asian Journal of Pharmaceutical and Clinical Research. 2009;2(1)81-6.