Effect of *Kungiliya vennai* and *Kalchunna thailam* on Excision Wound Healing in Albino wistar rats

Vishal Bhat,[1] Arul Amuthan,[1] Barizah Binti Mohamed Rosli,[2] Nur Amirah Binti Khairuddin,[2] Fatin Shahira Binti Md. Isa[2]

[1]*Department of Pharmacology, Melaka Manipal Medical College and Center for Integrative Medicine and Research,Manipal University, Karnataka-576104, INDIA.*
[2]*MBBS Student, Melaka Manipal Medical College, Manipal University, Karnataka-576104, INDIA.*

ABSTRACT

Background: *Kungiliya vennai* and *Kalchunna thailam* are the two indigenous herbal formulation being used for healing of wounds in siddha medicine. **Objectives:** The objective of our study was to evaluate the wound healing property of topical application of *kungiliya vennai* (KV) and *kalchunna thailam* (KT) on excision wound in Sprague Dawley rats. **Methods:** Four groups of eight Sprague dawley female rats in each group were used for the study. Under anesthesia, excision wound of 300mm^2 size was created using scissors. Group 1 served as control with no drugs applied. Group 2, 3 and 4 were applied with mupirocin, KV and KT respectively daily until wound was completely healed. Parameters observed were % wound contraction rate and epithelialization period. Biopsy of wound for histology was taken on day 12 as well as the healed wound was taken after the wound was healed. Results were analyzed by one-way analysis of variance (ANOVA) followed by Tukey's test by keeping $p<0.05$ as statistically significant. **Results:** *Kalchunna thailam* has increased wound contraction rate only during initial days, but not statistically significant. *Kungiliya vennai* treatment has increased vascularity with presence of tissue eosinophils when compared to control rats. There was a regeneration of adnexal skin structures in the *Kungiliya vennai* treated rats, which is not seen in other groups. The epithelialization period was significantly ($p<0.001$) hastened in Group 3 (15.83 days) and 4 (15.17 days) compared to control group (21.33 days). **Conclusion:** The topical application of k*ungiliya vennai* and *kalchunna thailam* promoted wound healing in rats. *Kungiliya vennai* has the additional property of regenerating adnexal structures such as hair follicles, sweat glands and sebaceous glands.

Key words: Siddha Medicine, *Shorea robusta*, Calcium, Wound, *Kungiliya vennai.*

Citation: Bhat V, Amuthan A, Rosli BBM, Khairuddin NAB, Md. Isa FSB. Effect of *Kungiliya vennai* and *Kalchunnam thailam* on excision wound healing in albino Wistar rats. Int J Pharmacol and Clin Sci. 2015;4(3):52-57.

INTRODUCTION

More than 80% of the world's population depends upon traditional medicines for various skin diseases.[1] The use of traditional medicine for wound healing has been gaining increasing interest across the world.[2] Approximately one-third of all traditional medicines in use are for the treatment of wounds and skin disorders, compared to only 1-3% of modern drugs.[3] Wound healing is a complex process characterized by homeostasis, reepithelization, and granulation tissue formation and remodeling of the extracellular matrix.[4]

Received : 15-05-2015 **Revised :** 18-08-2015;
Accepted : 28-08-2015
***Correspondence : Dr. Arul Amuthan,**
Lecturer, Department of Pharmacology,
Melaka Manipal Medical College
and Center for Integrative Medicine and Research,
Manipal University, Karnataka-576104, INDIA.
Ph no: 9986353238,
E-mail: dramuthanmd@yahoo.co.in
Conflict of interest: Nil ; **Source of support :** Nil

DOI : 10.5530/ijpcs.4.3.4

Reports about medicinal plants affecting various phases of the wound healing process, such as coagulation, inflammation, fibroplasia, collagenation, epithelization and wound contraction are abundant in the scientific literature.[5,6] This study is necessary to prove the effect of *Kungiliya vennai* and *Kalchunna thailam* in wound contraction.

Kungiliya vennai is an indigenous herbal formulation containing *Shorea robusta* (Sal-resin, Dipterocarpaceae), *Sesamun indicum* (til oil) and *Cocos nucifera* (tender coconut water) which claims to have the potential in the treatment of wounds, burns, cuts etc.[7] It is being practiced by Siddha practitioners for the treatment of wound and burn. *Shorearobusta* (two-winged fruit), is most commonly found in Indonesia, Malaysia, Philippines and Northern India.[8] The powdered stem, bark or resin is applied to stop bleeding and promote healing of cuts among the tribal inhabitants of southern Bihar and the Kondhsof south-western Odisha, India.[9]

The word '*chunnam*' is indicative of an alkaline product, similar to lime. In Tamil language, caustic lime is also termed as *chunnam*. The raw material for the manufacturing of caustic lime (calcium oxide, CaO) is limestone (calcium carbonate, $CaCO_3$). In wound repair, calcium is predominantly involved as Factor IV in the hemostatic phase, but it is expected to be required in epidermal cell migration and regeneration patterns in later stages of healing. *Kalchunna thailam* is a preparation of limestone and coconut oil in equal proportions and is indicated for healing of wounds in siddha medicine.[10] Coconut oil has long been used in the ayurveda system of medicine for various skin disorders including wound healing and microbial infections. Studies have shown that coconut oil significantly benefits wound healing in burn injuries by improving intracellular and extracellular matrix components.[11,12] Thus, the hypothesis of this study was *Kungiliya vennai* and *Kalchunna thailam* were effective in wound healing activity.

In the present study, *Kungiliya vennai* and *Kalchunna thailam* have been selected for the evaluation of wound healing activity in excision wound models in Sprague Dawley rats.

MATERIALS AND METHODS

Animals

The study was carried out at Central Animal house, KMC Manipal. Thirty two adult Sprague Dawley rats of female sex and weighing 150-200 g were used for the study. Animals were housed individually in polypropylene cages containing sterile paddy husk (procured locally) as bedding throughout the study and had free access to sterile food (animal chow) and water ad libitum. This study was conducted after obtaining animal ethical clearance.

Test drugs

Mupirocin 2% ointment (Sun Pharmaceutical Industries Ltd, Mumbai, India) was purchased from the market. *Kungiliya vennai* was procured from SKM Siddha and Ayurveda pharma, Erode, Tamil Nadu, India. *Kalchunna thailam* was prepared as per the Siddha Materia Medica literature.[10] Briefly, 1.34 Kg limestone was dissolved in 5.37 liter of distilled water and kept it for 3 days for the particles to settle down. On day 4, the clear superficial layer of water (*chunnampu neer*), was collected, which was known as lime water. 500 ml of lime water and 500 ml of coconut oil was mixed in a beaker and shaked well to get *kalchunna thailam*, a white colored gel.

Excision wound model

Animals in each group (n=8) were anaesthetized with ketamine 50 mg/kg, i.p. The rats were depilated on the back. One excision wound was inflicted by cutting away a 300 mm^2 full thickness of skin from a predetermined area. The wound was left undressed to the open environment. Then the test drugs and standard drug were administered topically from day 1 till complete wound healing was achieved.

Group 1 served as control and did not receive any topical drugs. Group 2, 3 and 4 received topical application of mupirocin, *kungiliya vennai* and *kalchunna thailam* respectively.

Parameters observed[13]

Wound contraction rate

It was noted by progressive changes in wound area planimetrically, excluding the day of the wounding. The size of the wounds was traced on a transparent paper every two days, throughout the monitoring period. The tracing was then transferred to 1 mm^2 graph sheet, from which wound surface area was evaluated. The evaluated surface area was then employed to calculate the percentage of wound contraction, taking the initial size of the wound, 300 mm^2, as 100% by using the following equation.

$$\% \text{ of wound contraction} = \frac{(\text{Initial wound size} - \text{Specific day wound size})}{\text{Initial wound size}} \times 100$$

Epithelization period

It was monitored by noting the number of days required for the eschar to fall off from the burn wound surface without leaving a raw wound behind.

Histological examination

Histological examination using Haematoxylin & Eosin staining of wound tissue as well as healed tissue were performed by taking biopsy using punch biopsy needle on day 12 and after the wound was completely healed respectively.

Statistical analysis

The result were analyzed using one-way analysis of variance (ANOVA) followed by Tukey's Test by keeping $p<0.05$ as statistically significant.

RESULT

Wound contraction rate

Kalchunna thailam treatment has shown increased wound contraction rate during the initial days, than all other groups. (Table-1, Figure-1)

Epithelization period

Kungiliya vennai and *Kalchunna thailam* treatment have significantly ($P<0.001$) hastened the epithelialization period (15.83 days and 15.17 days respectively) compared to control group (21.33 days).(Table-1, Figure-2)

Histology

During the day 12 of wound, the control, mupirocin and *Kalchunna thailam* treatment showed high thickness in sub epidermal tissue with extensive granulation tissue, and proliferative vessels with chronic inflammatory cells predominantly lymphocytes than macrophages. After the wound was healed, the histology revealed the absence of adnexal structures, reduced vascularity, and Increased fibrosis with absence of inflammatory cells in all the three groups (Figure 3-6).

On the other hand, the *Kungiliya vennai* treatment on day 12 has produced increased vascularity with presence of more tissue eosinophils in sub epithelium. In the healed wound, there was the regeneration of adnexal structure (Figure 5a,b).

The *Kalchunna thailam* treatment showed that there was an increase in vascularity with presence of tissue eosinophils

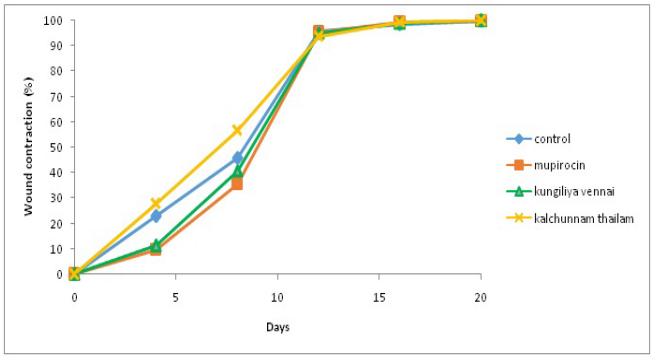

Figure 1: Effect of *kungiliya vennai* and *kalchunnam thailam* on wound contraction rate in rat excision wound

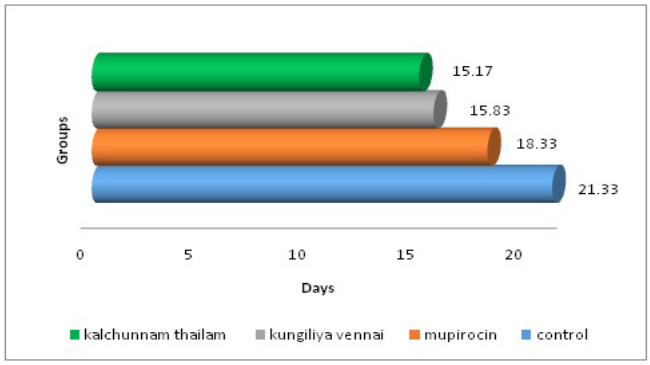

Figure 2: Effect of *kungiliya vennai* and *kalchunnam thailam* on epithelialization period

Table 1: Effect of *kungiliya vennai* and *kalchunnam thailam* on wound contraction rate and epithelialization period in rat excision wound

Groups	Wound contraction rate (%)					epithelialization period (days)
	day 4	day 8	day12	day16	day20	
control	22.92 ± 10.81	45.68 ± 8.62	95.97 ± 1.35	98.42 ± 0.72	99.74 ± 0.14	21.33 ± 0.92
mupirocin	9.64 ± 10.83	35.47 ± 4.59	95.44 ± 0.81	99.27 ± 0.40	99.84 ± 0.10	18.33 ± 1.45
kungiliya vennai	11.29 ± 4.00	40.65 ± 4.24	95.11 ± 1.57	98.90 ± 0.88	100.00 ± 0.00	15.83 ± 0.48*
kalchunnam thailam	27.95 ± 3.12	56.64 ± 3.57	93.66 ± 2.31	99.40 ± 0.60	100.00 ± 0.00	15.17 ± 0.70*

* $P<0.001$ vs. control.

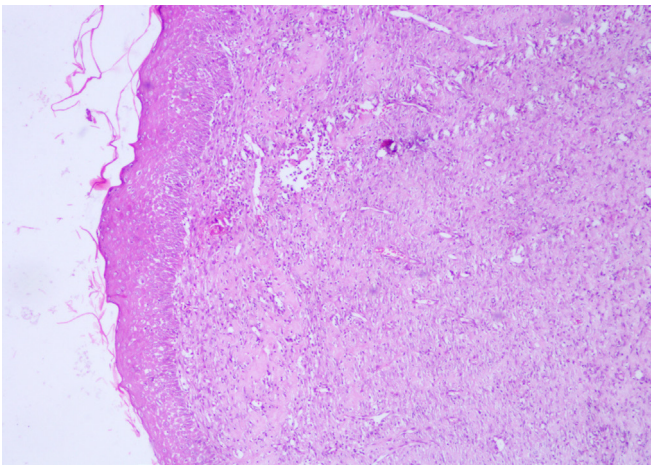

Figure 3a: Histology of wound on day 12 of control group
Showed thickened epidermis, sub epidermal tissue is thick with extensive granulation tissue, proliferative vessels with chronic inflammatory cells predominantly lymphocytes than macrophages, loose matrix with myofibroblast and absence of adnexal structure.

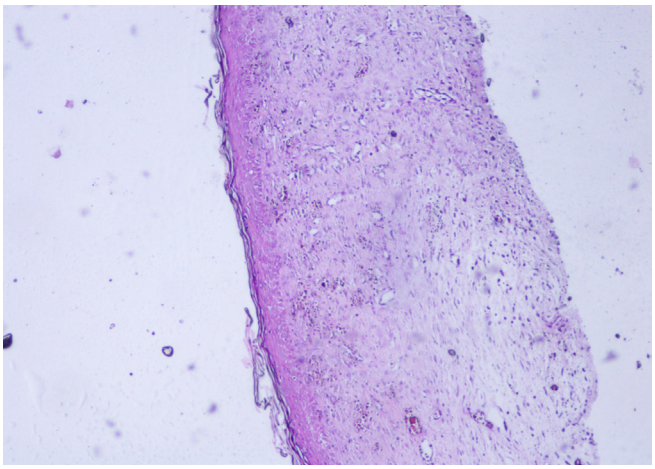

Figure 3b: Histology of healed wound of control group
Showed reduced epithelial thickness. Absence of adnexal structures. Late granulation tissues containing collagenous tissue with reduced vascularity. Increased fibrosis with absence of inflammatory cells.

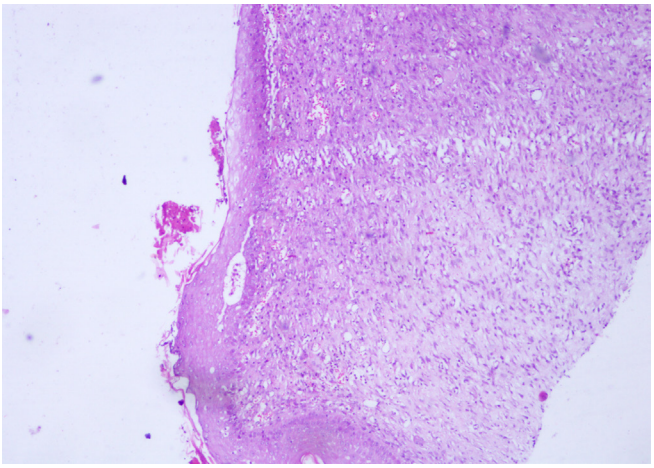

Figure 4a: Histology of wound on day 12 of mupirocin group
Showed same features as control.

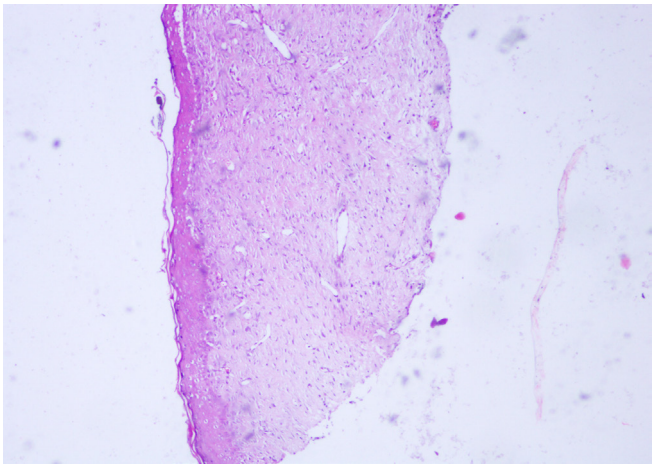

Figure 4b: Histology of healed wound of mupirocin group
Showed same features as control.

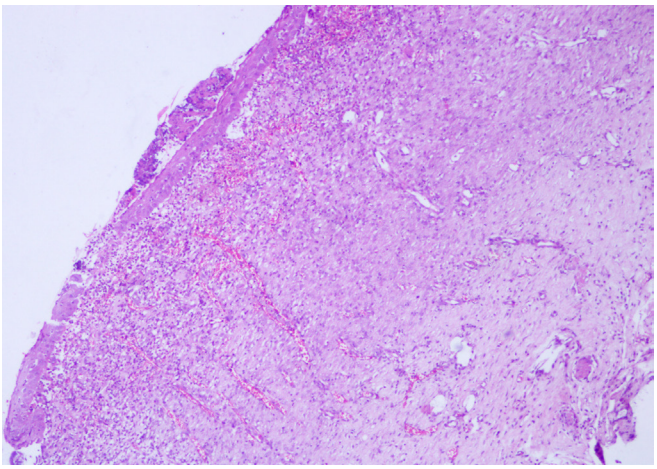

Figure 5a: Histology of wound on day 12 of *Kungiliya vennai* group
Showed lesser epidermal thickening than control, compact epidermis, underlying sub epithelial shows increased vascularity with presence of more tissue eosinophils.

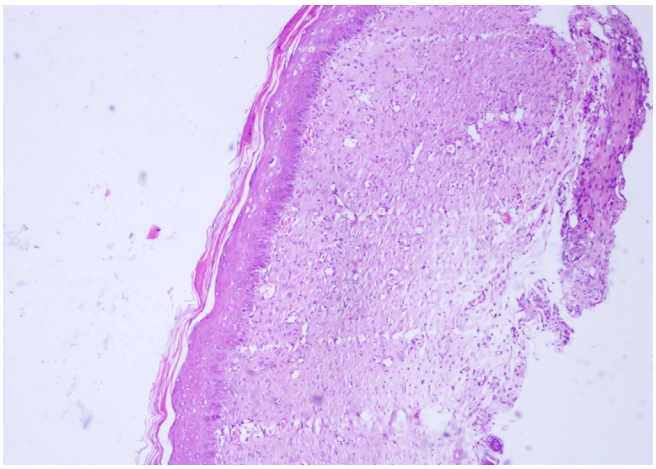

Figure 5b: Histology of healed wound of *Kungiliya vennai* group
Showed compact epithelium with restoration/regeneration of adnexal structure and hypovascular scar tissue.

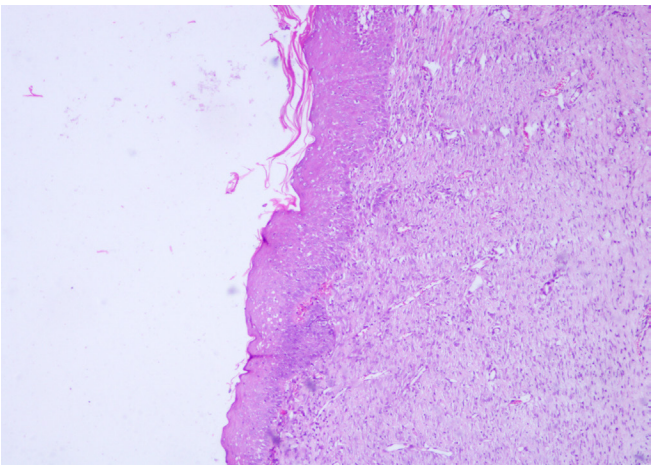

Figure 6a: Histology of wound on day 12 of *Kalchunna thailam* group Showed less thickness in epidermis, low vascularity, less inflammation and the intensity of granulation tissue is lower than control.

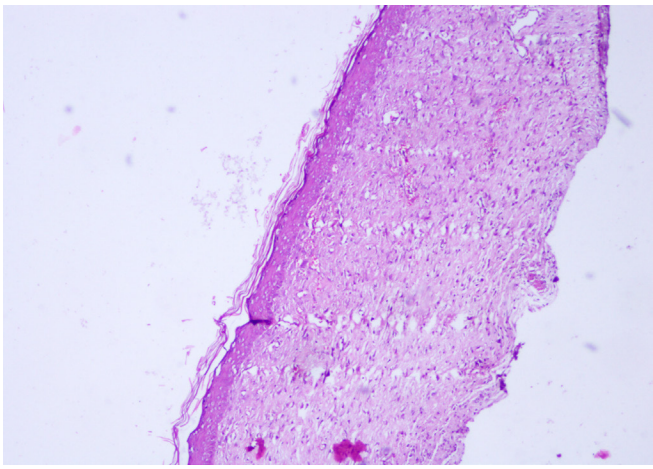

Figure 6a: Histology of healed wound of *Kalchunna thailam* group Showed more compact epidermis with no restoration of adnexal structure.

when compared to control rats. There was a regeneration of adnexal skin structures in the *Kungiliya vennai* treated rats, which is not seen in other groups (Figure 5b,6b).

DISCUSSION

Medicinal plants in wound healing are used for disinfection, debridement and the stipulation of appropriate environment for natural healing process. Indeed, alternate medicines are of less toxicity and with fewer side-effects compared with modern medicine and hence, it is significant to introduce a scientific validation for the medicinal values of plants used in traditional medicine.[14]

Wound healing is a complex natural renewal process of skin cells to curtail or eliminate scarring as well to help healing and repairing damage.[15] The major events include cellular migration, proliferation, adhesion and phenotypic differentiation. The present investigation of *Kungiliya vennai* and *kalchunnam thailam* administration on wounds has produced a positive outcome in the healing process.

Studies have shown that the eosinophil is one of the predominant cell types in the healing wound, beginning from the seventh day and thereafter. The majority of the eosinophils present in the healing wound were found to contain TGF-alpha mRNA and protein by in situ hybridization and immunohistochemistry. Thus, it is proposed that the delivery of TGF-alpha by eosinophils to epithelial wound healing sites represents a normal body mechanism whereby this multifunctional cytokine can accelerate the wound healing process.[16] The presence of increased eosinophils in histological staining of *kungiliya vennai* treated wounds, indicates the better wound healing in these animals.

Our study has created scientific preclinical evidence for using *kungiliyavennai* and *kalchunnamthailam* for the management of wounds by Siddha physicians. However, further studies on the phytochemicals responsible for healing effect, their molecular mechanisms and clinical studies to be warranted.

ACKNOWLEDGEMENT

Authors would like to thank SKM Siddha and Ayurveda pharma, Erode, Tamil Nadu, India for providing free samples of *Kungiliya vennai* for the study purpose.

REFERENCES

1. Annan K, Houghton PJ. Antibacterial, antioxidant and fibroblast growth stimulation of aqueous extracts of *Ficusasperifolia* Miq. And Gossypiumarboreum L., wound-healing plants of Ghana. J Ethnopharmacol. 2008;119(1):141-4.
2. Houghton PJ, Hylands PJ, Mensah AY, Hensel A, Deters AM. In vitro tests and ethnopharmacological investigations: wound healing as an example. J Ethnopharmacol. 2005;100(1-2):100-7.
3. Mantle D, Gok MA, Lennard TW. Adverse and beneficial effects of plant extracts on skin and skin disorders. Adverse Drug React. Toxicol Rev. 2001;20(2):89-103.
4. Priya KS, Gnanamani A, Radhakrishnan N, Babu M. Healing potential of *Datura alba* on burn wounds in albino rats. J Ethnopharmacol. 2002;83(3):193-9.
5. Asif A, Kakub G, Mehmood S, Khunum R, Gulfraz M. Wound healing activity of root extracts of *Berberis lyceum*royle in rats. Phytother Res. 2007;21(6):589-91.
6. Hemmati AA, Mohammadian F. An investigation into the effects of mucilage of quince seeds on wound healing in rabbit. J Herbs Spices Med Plants. 2000;7(4):41-6.

7. Therapeutic Index–Siddha. India: SKM Siddha and Ayurveda drug Manufacture; 2000: p.221.
8. Wani TA, Chandrashekhara HH, Kumar D, Prasad R, Gopal A, Sardar KK. Wound healing activity of ethanolic extract of *Shorearobusta* Gaertn. f. resin. Indian J Experimental Biol. 2012;50(4):277-81.
9. Ganesan S, Venkateshan G, Bhanumathy N. Medicinal plants used by ethnic group Thottianaickans of Semmalai hills, Tiruchirrapalli district, Tamil Nadu. Indian J TraditKnowl. 2006;5(2):245–52.
10. Pillai CK. Siddha Materia Medica (Mineral-Animal Kingdom). India: B RathnaNayakar and sons, Chennai;1997.p.91.
11. Nevin KG, Rajamohan T. Effect of Topical Application of Virgin Coconut Oil on Skin Components and Antioxidant Status during Dermal Wound Healing in Young Rats. Skin Pharmacol Physiol. 2010;23(6):290-7.
12. Sachs M, Von Eichel J, Asskali F. Wound management with coconut oil in Indonesian folk medicine (Article in German). Chirurg. 2002;73(4):387-92.
13. Verma DK, Bharat M, Nayak D, Shanbhag T, Shanbhag V, Rajput RS. Areca catechu: Effect of topical ethanolic extract on burn wound healing in albino rats. Int J Pharmacol and ClinSci. 2012;1(3):74-8.
14. Priya KS, Gnanamani A, Radhakrishnan N, Babu M. Healing potential of Datura alba on burn wounds in albino rats. J Ethnopharmacol. 2002;83(3):193-9.
15. Eming SA, Werner S, Bugnon P, Wickenhauser C, Siewe L, Utermöhlen O. Accelerated wound closure in mice deficient for interleukin-10. Am J Pathol. 2007;170(1):188-202.
16. Todd R, Donoff RB, Chiang T, Chou MY, Elovic A, Gallagher GT. The eosinophil as a cellular source of transforming growth factor alpha in healing cutaneous wounds. Am J Pathol. 1991;138(6):1307-13.